

# Ophthalmology<sup>TM</sup> ROUNDS

APRIL 2004  
Volume 2, Issue 4

AS PRESENTED IN THE  
ROUNDS OF THE DEPARTMENT  
OF OPHTHALMOLOGY  
AND VISION SCIENCES,  
FACULTY OF MEDICINE,  
UNIVERSITY OF TORONTO

## Phacoemulsification Techniques and Innovations

BY ROSA BRAGA-MELE, M.ED, MD, FRCSC

Cataract surgery and phacoemulsification techniques have advanced dramatically over the past 10 years. The trend has been towards less traumatic surgery by using ultrasound-assisted phacoaspiration instead of vacuum-assisted phacoemulsification. Recent refinements in power modulations have led most surgeons to use techniques that utilize less phacoemulsification energy, thus reducing thermal energy delivery and injury to the eye.<sup>1,2</sup> This is accomplished by using either mechanical forces to disassemble the nucleus, higher vacuum levels to aspirate it, or a combination of both. This issue of *Ophthalmology Rounds* describes the "quickchop" phacoemulsification and bimanual microincisional phacoemulsification techniques that attempt to simplify each stage of the cataract operation to minimize trauma and achieve an optimal outcome.

### The "quickchop" phacoemulsification technique

The cataract surgeon can encounter many challenging scenarios when performing phacoemulsification surgery. It is important to know what to expect when dealing with a challenging case and to have a gameplan ready to facilitate the surgery. Although most surgeons are more comfortable with a particular technique, it is essential to be flexible and vary techniques depending on the situation. Preoperative assessment of the patient and determining the type of cataract and morphology of the eye (eg, axial length, zonular instability, post-traumatic, post-surgical) can help in deciding how to proceed with the case.

Preoperative treatment with topical medications can make the intraoperative and postoperative course more predictable. Topical nonsteroidal anti-inflammatory drugs (NSAIDs) are helpful for maintaining intraoperative mydriasis and controlling postoperative inflammation, thus reducing the need for long-term topical steroid usage. NSAIDs have also been proven to help in preventing chronic macular edema.<sup>3</sup> Preoperative NSAIDs can be given 4 times a day, starting on the day prior to surgery; and continued immediately post-surgery for a month. The use of preoperative antibiotics, such as the fluoroquinolones, may also help prevent postoperative infections. Fluoroquinolones can begin a day prior to surgery and may be continued for 2 weeks post-surgery along with a steroid eyedrop.

Surgery is performed using a clear cornea temporal approach. Topical tetracaine is usually adequate to provide satisfactory anaesthesia. However, if iris manipulation



FACULTY OF MEDICINE  
*University of Toronto*



Department of  
Ophthalmology and  
Vision Sciences

#### Department of Ophthalmology and Vision Sciences

Jeffrey Jay Hurwitz, MD, Editor  
*Professor and Chair*  
Martin Steinbach, PhD  
*Director of Research*

**The Hospital for Sick Children**  
Elise Heon, MD  
*Ophthalmologist-in-Chief*

**Mount Sinai Hospital**  
Jeffrey J. Hurwitz, MD  
*Ophthalmologist-in-Chief*

**Princess Margaret Hospital  
(Eye Tumour Clinic)**  
E. Rand Simpson, MD  
*Director, Ocular Oncology Service*

**St. Michael's Hospital**  
Alan Berger, MD  
*Ophthalmologist-in-Chief*

**Sunnybrook and Women's College  
Health Sciences Centre**  
William S. Dixon, MD  
*Ophthalmologist-in-Chief*

**The Toronto Hospital  
(Toronto Western Division and  
Toronto General Division)**  
Robert G. Devenyi, MD  
*Ophthalmologist-in-Chief*

Department of Ophthalmology  
and Vision Sciences,  
Faculty of Medicine,  
University of Toronto,  
60 Murray St.  
Suite 1-003  
Toronto, ON M5G 1X5

The editorial content of  
*Ophthalmology Rounds* is determined  
solely by the Department of  
Ophthalmology and Vision Sciences,  
Faculty of Medicine, University of Toronto

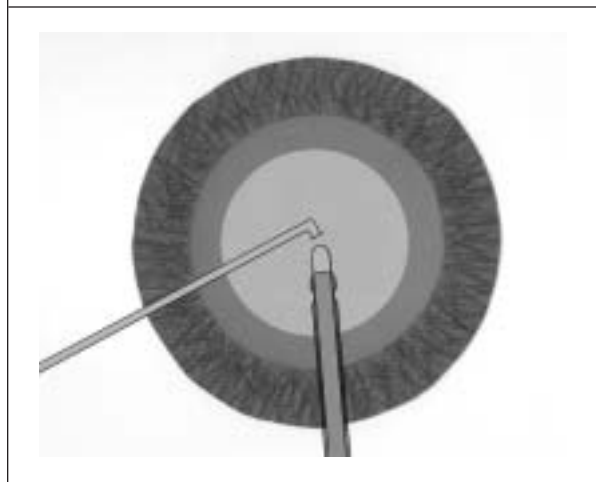
**Available on the Internet at:** [www.ophthalmologyrounds.ca](http://www.ophthalmologyrounds.ca)

is planned or the patient is particularly sensitive, intracameral non-preserved 1% lidocaine may be injected at the start of the case. A side-port incision is made on the left with a 15° metal blade. The anterior chamber is then filled with a viscoelastic (eg, a cohesive viscoelastic such as Amvisc Plus,<sup>®</sup> Bausch and Lomb, Rochester, NY) that allows maximum chamber and iris stability. However, if there is any indication of corneal compromise, Arshinoff's soft shell technique<sup>4</sup> is preferred, utilizing a more dispersive viscoelastic (eg, Viscoat,<sup>®</sup> Alcon, Fort Worth, Texas) as an adjunct to help coat the corneal endothelium. With Arshinoff's technique, the dispersive viscoelastic is injected initially to fill about half of the anterior chamber, followed by a cohesive viscoelastic that will force the dispersive up against the cornea. If the eye has a shallow anterior chamber or the pupil is small, one of the newer viscoadaptive substances (eg, Healon 5, Ivic phaco) can assist in deepening the anterior chamber and stretching the pupil due to their ability to better retain a given space. A clear corneal temporal incision, measuring 2.0 mm in length, can then be made using a 2.65 mm metal blade.

Continuous curvilinear capsulorhexis is performed using Utrata capsulorhexis forceps while holding onto the eye at the side-port using 0.12 forceps. This is followed by Fine's technique of cortical cleavage hydrodissection<sup>5</sup> in which a Gimbel cannula is inserted beneath the edge of the capsule, lifting it up initially, and then injecting a small bolus of fluid. Lens rotation within the capsular bag is always assessed before commencing phacoemulsification.

For phacoemulsification, it is important to understand the fluid dynamics associated with the machine being used to better predict the progression of the surgery. The phacoemulsification quickchop technique was first introduced by Nagahara. With this technique, a 30° bevel phaco needle is introduced into the eye with the bevel side down. It is important to retract the silicone sleeve to expose more of the metal needle in order to maximize a deeper purchase when using the

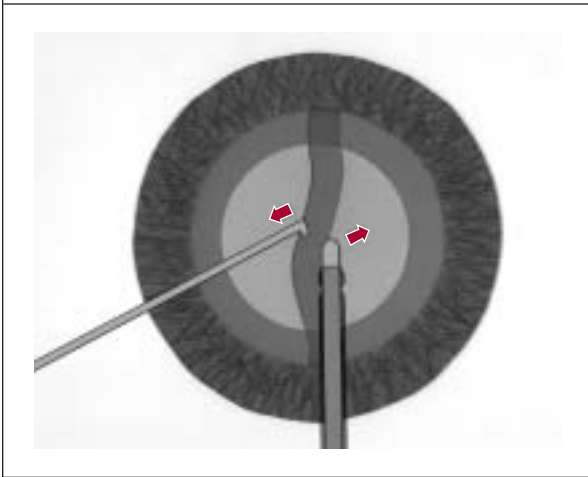
**Figure 1: Initial position for vertical quickchop**



quickchop technique. A Koch chopper (Storz, St. Louis, MO) is then placed just proximal to the center of the nucleus (Figure 1). The phaco tip then deeply impales the central nucleus in a bevel down position in the burst mode of 100 msec at 20% power. The burst mode power modulation uses a fixed percentage of power, a programmable burst width (duration of power), and a linear interval between bursts. The nucleus is initially impaled using a lower flow and vacuum setting, which is then increased once purchase or hold is achieved. In the same instant, the chop instrument is placed just in front or to the side of the buried phaco needle (Figure 1). The distal tip of the chopper is pressed down and to the left, as the phaco needle is moved slightly up and to the right (Figure 2). The chopper should be directed to the side of the phaco needle so that occlusion of the phaco tip on the nuclear fragment is not broken. The chopper and phaco tip are then spread further apart laterally to allow the cleavage plane to propagate entirely from one end of the nucleus to the other and through the posterior plate, which is a thicker piece of epinucleus that can be found in denser cataracts. It is important to verify that the chop is completely propagated before proceeding to the next step.

The nucleus is then rotated, re-impaled with the bevel turned on its side (to allow for parallel alignment and maximum purchase on the

**Figure 2: Propagation of chop through endonucleus.** Arrows denote movement of instruments.



nucleus) and the vertical downward chop repeated. The segment of nucleus that has been chopped is then brought out to the supracapsular space with the phaco needle and high vacuum and flow rates are used, aided by short bursts of phaco power to help direct the nuclear material into the phaco tip. This allows the phaco tip to stay central and in a safe zone. It is best to keep the chop instrument or manipulator turned on its side behind the piece of nuclear material being evacuated to protect the posterior capsule. Also, if the initial segment that was chopped is too large, it should be chopped into smaller segments that are easier to manipulate. As the last segment bits are being emulsified, the vacuum or flow should be lowered, since this allows more control of anterior chamber stability and less effects of surge. This process is repeated until the nucleus is completely removed.

After evacuation of the nucleus, the phaco tip engages the epinuclear rim under low vacuum or flow settings. As the epinuclear rim starts to pull away from the capsular bag, a second instrument, either a chopper or manipulator, is used to push on the epinuclear floor in a gentle upward rolling motion to assist in directing the evacuation of the epinucleus.

If there is remaining cortex, it is removed using a 45° irrigation/aspiration hand piece, at vacuum levels up to 500 mm Hg. If subincisional

cortex is difficult to remove, it is useful to separate irrigation and aspiration and use a bimanual technique for removal.

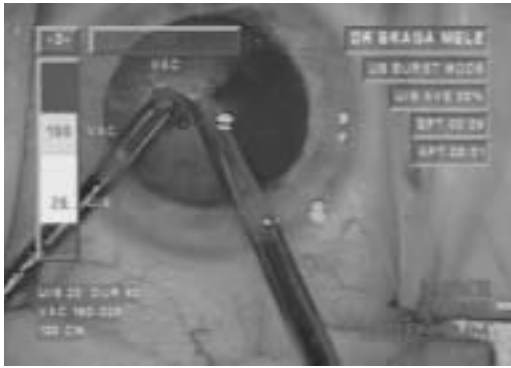
The capsular bag is then filled with viscoelastic and an intraocular lens is inserted into the capsular bag. Once the viscoelastic is removed from the eye, the wound is hydrated and checked for integrity and leakage.

### **Bimanual microincisional cataract surgery**

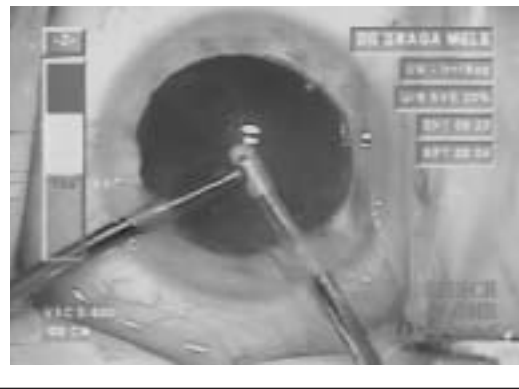
Advances in technology have brought about exciting improvements in cataract surgery techniques. It is a rapidly evolving field and surgeons are always looking for ways to perform the least traumatic surgery possible by either decreasing thermal energy delivery to the eye, decreasing wound size, or decreasing trauma to the cornea, thereby promoting a more rapid visual recovery. Refinements in power modulations<sup>1</sup> and control have allowed reductions in the total amount of ultrasonic energy delivered into the eye and, therefore, less risk of injury to the corneal endothelium and incision area.

Burst mode is one of the newer refinements. Due to shorter bursts of phacoemulsification power, followed by quiet intervals in which essential vacuum removes the fragment, this modality definitely optimizes ultrasound-assisted phaco-aspiration by minimizing ultrasound energy into the eye and maximizing the hold on the nuclear fragment. When used in conjunction with dual-linear control of the vacuum, this technique is ideal if using the quickchop technique, since it allows for more effective cutting and better follow-through. A recent study<sup>7,8</sup> examined absolute phaco times, comparing burst mode (160 msec) and pulse mode (5 pps), with the vacuum set at 180-325 mm Hg linear control and the bottle height set at 120 cm. Each group of 25 patients had either 2+ or 3+ nuclear sclerosis (Wilmer classification) and had their cataracts removed using the quickchop technique with either burst mode or pulse mode. There was a significant 50% reduction in total and absolute phaco times in the group utilizing burst mode.

**Figure 3a: Sleeveless microincisional phacoemulsification**



**Figure 3b: Bimanual irrigation and aspiration**



The most recent movement in phacoemulsification has been towards small-incision, bimanual, sleeveless (bare needle) phacoemulsification, anticipating the advent of a smaller foldable, rollable, or even injectable intraocular lens. Although a lens that can fit through a small stab incision is currently not available, there are 4 significant advantages when lens extraction is accomplished through 2 smaller incisions.<sup>1,6</sup>

- Irrigation through the side-port instrument can assist in moving lens material toward the phacoemulsification needle tip because, when irrigation is delivered through the sleeve, the irrigation fluid may potentially create a current that may push the lens material away from the needle tip. Separating the irrigation from aspiration should theoretically direct loose pieces towards the aspiration port.
- Nuclear material can be approached from 2 different incision sites if needed.
- Subincisional cortex can be more easily removed.
- Small stab incisions allow for a tightly closed and stable anterior chamber.

Agarwal<sup>9</sup> reported success using the Phakonit method of bimanual lens extraction though a 0.9 mm incision with a sleeveless phacoemulsification needle. Recent research with the Millennium Microsurgical System (Bausch & Lomb, Rochester, New York) and the Sovereign phacoemulsification

unit (AMO, California) demonstrated that “microphaco,” using a bare phaco needle through a relatively small incision, could be conducted using specific parameters on these machines.<sup>10-12</sup>

A clinical study is currently underway using the previously described quickchop technique on cataracts ranging from 2+ to 4+ nuclear sclerosis. Phacoemulsification with the Millennium Microsurgical System using burst mode at 100 msec burst width intervals is performed with a bare, sleeveless, Micro-Flow 30° bevel phaco needle through a 1.4 mm incision made with a diamond blade. This wound size allows for the 1.1 mm phacoemulsification tip to enter the eye without any strain on the wound and a small amount of egress fluid allows cooling of the wound without chamber compromise (Figure 3a). Irrigation is also employed through a 1.4 mm side port incision using a 19 gauge irrigating chopper with 2 side irrigating ports (Figure 3b). An irrigating chopper with 2 side-ports rather than one main central port is felt to improve the fluid dynamics within the anterior chamber, thus allowing currents to direct nuclear fragments to the phacoemulsification tip rather than a direct stream of fluid potentially pushing fragments away. Vacuum levels are set on the Millennium System using venturi mode to vary within 180-325 mm Hg using dual-linear technology and bottle



height set at 125 centimeters. The ability to vary the vacuum allows the surgeon the necessary control during bimanual phacoemulsification to titrate the vacuum level according to the fluidics and thereby, minimize the occurrence of anterior chamber instability. For example, the surgeon could use high vacuum when the tip is fully occluded and holdability is necessary to ensure an efficient chop technique. However, once occlusion is broken, the surgeon can turn down the high vacuum to a level that allows efficient removal of the segment, but still allows a stable anterior chamber.

Using the above parameters and techniques, phacoemulsification can be performed safely and effectively with a bimanual sleeveless procedure and with no trauma or burns to the wounds. Absolute phaco times range from 1 to 7 seconds in these cases and the average case time from skin to skin is about 2 minutes longer than conventional phacoemulsification techniques. The wounds are invariably clear on the first postoperative day with negligible corneal edema.

## Conclusion

Being able to refine power, modulate fluids, and utilize more mechanical force with techniques such as quickchop to remove cataracts has resulted in less energy being delivered into the eye and ultimately better outcomes for patients. Cataract surgery has become an exciting and innovative field and the creativity of cataract surgeons will undoubtedly lead to even more refinements in technique and technology, adding to what is already one of the most successful operations in all of medicine.

---

*Rosa Braga-Mele, M.Ed, MD, FRCSC, is an Assistant Professor, University of Toronto, and Director of the Cataract Unit and Surgical Teaching, Mount Sinai Hospital.*

---

## References

1. Fine IH, Packer M, Hoffman R. New phacoemulsification technologies. *J Cataract Refract Surg* 2002;28:1054-1060.
2. Fine IH, Packer M, Hoffman R. Use of power modulations in phacoemulsification-Choo-choo chop and flip phacoemulsification. *J Cataract Refract Surg* 2001;27:188-197.
3. McColgin AZ, Heier JS. Control of intraocular inflammation associated with cataract. *Curr Opin Ophthalmol* 2000;11(1):3-6.
4. Arshinoff SA. Dispersive-cohesive viscoelastic soft shell technique. *J Cataract Refract Surg* 1999;25:167-173.
5. Fine IH. Cortical cleaving hydrodissection. *J Cataract Refract Surg* 1992;18:508-512.
6. Tsuneoka H, Shiba T, Takahashi Y. Ultrasonic phacoemulsification using a 1.4 mm incision: Clinical results. *J Cataract Refract Surg* 2002;28:81-86.
7. Braga-Mele R. Control of vacuum and phaco power for safe, efficient emulsification; *Ocular Surgery News* 2002;20(23):13-14.
8. Braga-Mele R. A presentation at the American Society of Cataract and Refractive Surgery Meeting, June 2002, Philadelphia, PA.
9. Agarwal A, Agarwal S, Agarwal A. Phakonit and laser phakonit lens removal through 0.9 mm incision. In: Agarwal A, Agarwal S, Sachdev MS, et al. *Phacoemulsification, Laser Cataract Surgery and Foldable IOLs*. New Delhi: Jaypee Brothers;1999.
10. Braga-Mele R, Lui E. Feasibility of sleeveless bimanual phacoemulsification on the Millennium Microsurgical System; *J Cataract Refract Surg* 2003;29:2199-2203.
11. Braga-Mele R. Sleeveless bimanual phaco with Millennium system delivers less thermal energy to the eye. *Ocular Surgery News* 2003;21(7):43.
12. Soscia W, Howard J, Olson R. Bimanual phacoemulsification through 2 stab incisions. A wound temperature study. *J Cataract Refract Surg* 2002;28:1039-1043.

## Abstracts of Interest

### Feasibility of sleeveless bimanual phacoemulsification with the Millennium microsurgical system.

BRAGA-MELE R, LIU E. TORONTO, ONTARIO

**PURPOSE:** To assess the feasibility of sleeveless bimanual phacoemulsification using the Millennium Microsurgical System (Bausch and Lomb Surgical) by measuring wound temperature during phacoemulsification.

**SETTING:** In vitro laboratory.

**METHODS:** The Millennium system was used in 6 eye-bank eyes using pulse mode and 80-millisecond and 160-millisecond phaco burst mode with intervals. Wound temperatures were measured, and the wounds were observed for thermal injury.

**RESULTS:** In pulse mode and the nonoccluded state at 100% power, the maximum temperature was 43.8 degrees C. In the occluded state at 30%

power, the maximum temperature was 51.7 degrees C after 70 seconds of occlusion. In phaco burst mode with a 160-millisecond burst-width interval, the maximum temperature was 41.4 degrees C (nonoccluded at 100% power). At 80% power, the maximum temperature was 53.2 degrees C within 60 seconds of full aspiration occlusion with the footpedal fully depressed. With an 80-millisecond burst-width interval in the nonoccluded and occluded states (100% power, footpedal fully depressed for 3 minutes), there was no significant temperature rise. The maximum temperature was 33.6 degrees C in the nonoccluded state and 41.8 degrees C in the occluded state. In all instances, the corneal wound remained clear. No wound burn or contracture was noted.

**CONCLUSIONS:** The demonstrated temperature rises were under clinically unusual parameters. Phacoemulsification with a sleeveless needle through a small stab incision can be safely performed with the Millennium system using conventional phaco burst mode settings within certain parameters.

*J Cataract Refract Surg* 2003;29(11):2199-203.

### New phacoemulsification technologies

FINE IH, PACKER M, HOFFMAN RS.  
EUGENE, OREGON

To examine recent developments in the field of phacoemulsification, a literature review was conducted for each system described. The review included peer-reviewed articles, information from manufacturers, and meeting presentations by surgeons. Our personal experience with systems we have used forms the underlying basis of our evaluation. Data for erbium: YAG laser phacoemulsification came from an interim summary of the U.S. Food and Drug Administration monitored study. Data for NeoSoniX came from a prospective evaluation of phacoemulsification in 25 eyes performed at the Oregon Eye Surgery Center. The development of new technology has allowed safer, more efficient phacoemulsification. Each surgeon should evaluate new developments to achieve the greatest possible benefit for patients.

*J Cataract Refract Surg* 2002;28(6):1054-60.

### Upcoming Scientific Meeting

4-5 June 2004

**Age-related Macular Degeneration Update 2004**

Baltimore, Maryland

CONTACT: Tel.: 410-955-5880

Email: cmenet@jhmi.edu

16-19 June 2004

**Canadian Ophthalmological Society Annual Meeting**

Vancouver, British Columbia

CONTACT: kross@eyesite.ca

Website: www.eyesite.ca

### Upcoming Department Events

**May 6, 2004**

VPP – Dr. Kathleen Digre, Salt Lake City, Utah

*Neuro-ophthalmic changes in pregnancy*

**May 13, 2004**

VPP – Dr. Shaun Singer, Toronto, ON

*Quality Assurance Rounds*

**May 20, 2004**

VPP – Dr. David Apple, Charleston, North Carolina

*U of T & TOS combined Rounds, Vaughan Estates*

**May 27, 2004**

VPP – Dr. Marian Macsai, Glenview, Illinois

*Refractory blepharomeibomitis – The bread & butter of your clinical practice*

**June 4, 2004**

Research Day - U of T Koffler Auditorium

Contact: Sertina Law – 416-603-5663

**June 16-19, 2004** – COS, Vancouver

**Note:** Visiting Professors Programme (VPP) site address:

Toronto Western Hospital, West Wing, Room 2 - 401,  
399 Bathurst Street, Toronto.

Change of address notices and requests for subscriptions for *Ophthalmology Rounds* are to be sent by mail to P.O. Box 310, Station H, Montreal, Quebec H3G 2K8 or by fax to (514) 932-5114 or by e-mail to info@snellmedical.com. Please reference *Ophthalmology Rounds* in your correspondence. Undeliverable copies are to be sent to the address above. Publications Post #40032303

This publication is made possible by an unrestricted educational grant from

## Novartis Ophthalmics

© 2004 Department of Ophthalmology and Vision Sciences, Faculty of Medicine, University of Toronto, which is solely responsible for the contents. Publisher: SNELL Medical Communication Inc. in cooperation with the Department of Ophthalmology and Vision Sciences, Faculty of Medicine, University of Toronto. ®*Ophthalmology Rounds* is a registered trademark of SNELL Medical Communication Inc. All rights reserved. The administration of any therapies discussed or referred to in *Ophthalmology Rounds* should always be consistent with the approved prescribing information in Canada. SNELL Medical Communication Inc. is committed to the development of superior Continuing Medical Education.