

# Ophthalmology<sup>®</sup> ROUNDS

AS PRESENTED IN THE  
ROUNDS OF THE DEPARTMENT  
OF OPHTHALMOLOGY  
AND VISION SCIENCES,  
FACULTY OF MEDICINE,  
UNIVERSITY OF TORONTO

## Pupillary anatomy, physiology, and related disorders

BY EDWARD MARGOLIN, MD, FRCSC, AND CLARA C. CHAN, MD

Knowledge of pupillary anatomy and physiology is essential for any practicing ophthalmologist. This knowledge provides a wealth of information about visual pathways that can guide clinicians in differentiating relatively minor conditions from life-threatening illnesses. This issue of *Ophthalmology Rounds* provides a general overview of pupillary anatomy and physiology and of some common disorders involving pupillary signs.

### Anatomy of the pupil

The pupil is the opening in the centre of the iris that controls the amount of light entering the eye. The size and reactivity of the pupils are regulated by the parasympathetic and sympathetic nervous systems. A pathology that involves parasympathetic input to the pupil will cause pupillary dilation (mydriasis) and prevent normal constriction in response to light or near target. Disorders involving the sympathetic pathways that innervate the iris dilator muscle will cause a smaller pupil on the affected side and delayed dilation in dim light.

### Parasympathetic pathways

#### Regulation of pupillary light reflex

The light reflex process is diagrammed in Figure 1. The optic nerve, where the ganglion cell axons from the retina converge, carries light input to the optic chiasm. There, nasal retinal fibres (temporal visual field) decussate to continue in the contralateral optic tract and the temporal retinal fibres (nasal visual field) continue in the ipsilateral optic tract. Approximately two-thirds of the distance along the optic tract, some retinal ganglion cell axons carrying afferent light signals leave the optic tract, enter the brachium of the superior colliculus at the midbrain, and synapse in the pretectal nuclei on each side. At that point, fibres decussate dorsally and ventrally around the sylvian aqueduct and synapse in the Edinger-Westphal (EW) nucleus in the pretectal midbrain. Decussation of fibres from each pretectal nucleus ensures that pupillary response to light is consensual. From the EW nucleus parasympathetic fibres travel along the surface of the ipsilateral oculomotor nerve where they are vulnerable to compression but spared in ischemic vasculopathies because the damage is preferentially in the core of the nerve. Associated with the third (III) cranial nerve, parasympathetic fibres travel through the cavernous sinus and then enter the orbit through the superior orbital fissure. In the orbit, they synapse in the ciliary ganglion and travel to the iris sphincter muscle (~3% of all fibres) and to the ciliary body (~97%) via the short ciliary nerve.

### Near response/reflex

The near response triad consists of ocular convergence, lens accommodation, and pupillary miosis. It is postulated to originate in the occipital association cortex. The pathway for near response is located more ventrally in the midbrain than the afferent portion of the light reflex, providing an anatomical basis for "central" pupillary light-near dissociation in the context of a dorsal midbrain compressive lesion. Since fibres respon-



FACULTY OF MEDICINE  
*University of Toronto*



Department of  
Ophthalmology and  
Vision Sciences

### Department of Ophthalmology and Vision Sciences

Jeffrey Jay Hurwitz, MD, Editor  
*Professor and Chair*  
Martin Steinbach, PhD  
*Director of Research*

**The Hospital for Sick Children**  
Elise Heon, MD  
*Ophthalmologist-in-Chief*

**Mount Sinai Hospital**  
Jeffrey J. Hurwitz, MD  
*Ophthalmologist-in-Chief*

**Princess Margaret Hospital  
(Eye Tumour Clinic)**  
E. Rand Simpson, MD  
*Director, Ocular Oncology Service*

**St. Michael's Hospital**  
Alan Berger, MD  
*Ophthalmologist-in-Chief*

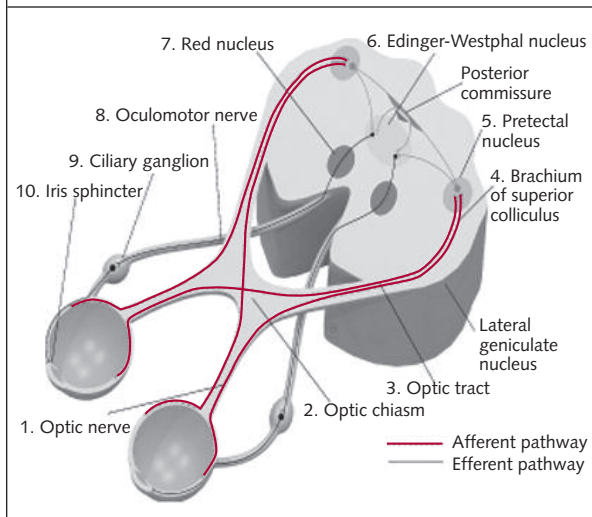
**Sunnybrook Health  
Sciences Centre**  
William S. Dixon, MD  
*Ophthalmologist-in-Chief*

**University Health Network  
Toronto Western Hospital Division**  
Robert G. Devenyi, MD  
*Ophthalmologist-in-Chief*

Department of Ophthalmology  
and Vision Sciences,  
Faculty of Medicine,  
University of Toronto,  
60 Murray St.  
Suite 1-003  
Toronto, ON M5G 1X5

The editorial content of  
*Ophthalmology Rounds* is determined  
solely by the Department of  
Ophthalmology and Vision Sciences,  
Faculty of Medicine, University of Toronto

**Figure 1: The light-reflex process in the optic nervous system**



sible for the light reflex travel from the pretectal nuclei to the EW nuclei through the dorsal midbrain and fibres responsible for accommodation travel through the ventral midbrain, the reaction to light is impaired, but constriction to a near target is preserved.

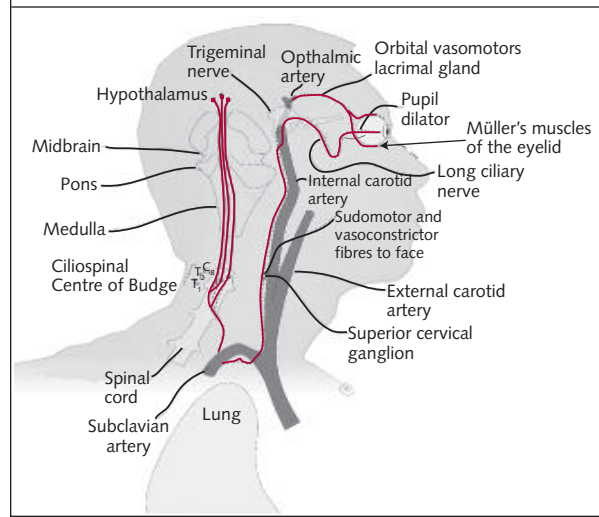
### Sympathetic pathways

#### Innervation of the iris dilator muscle

The sympathetic system involves a very complex 3-neuron pathway for innervating the dilator muscle of the iris and is illustrated in Figure 2.

- The first-order (central) neurons originate in the hypothalamus. The fibres then descend into the brainstem and spinal cord to synapse in the cilio-spinal centre of Budge located in the intermediolateral columns of the spinal cord at the level of cervical (C) 8 to thoracic (T) 2.
- Second-order (preganglionic) neurons exit from the spinal cord and travel through the sympathetic paraspinal chain to synapse in the superior cervical ganglion at the level of the jaw. On this path, the neurons pass through the mediastinum, where they course around the apex of the lung, the subclavian and jugular veins, and the brachial plexus.
- Third-order (postganglionic) neurons exit the superior cervical ganglion and form a plexus surrounding the external carotid artery. From there, the fibres that innervate the face follow the external carotid artery and the rest enter the skull base through the carotid canal. These fibres travel through the middle cranial fossa into the cavernous sinus where they briefly join the sixth cranial nerve prior to joining the ophthalmic division of the trigeminal nerve (V1) entering the orbit. Subsequently, they branch off with the nasociliary branch of the V1 and enter the orbit through the

**Figure 2: The 3-neuron pathway of the sympathetic optic nervous system**



superior orbital fissure. In the orbit, they pass through the ciliary ganglion without synapsing and eventually reach their final destination innervating the dilator muscle of the pupil, the Müller muscle of the eyelid, the lacrimal glands, and other structures.

### Testing pupillary function

The examination of pupillary function is a key feature in any ophthalmological examination and provides a wealth of information to the clinician. The patient should be instructed to fixate on a distant target to diminish variations in pupillary size produced by the near reflex. Lighting should be as dim as possible to allow the measurement of pupil size with minimal parasympathetic input. First, a light is shone in each pupil separately and the size in dim and bright illumination is measured. In dim light, a difference in the pupillary size (anisocoria) of up to 0.4 mm is found in almost 50% of normals. A difference of up to 1.5 mm is most often still due to physiological anisocoria; however, anisocoria >1.5 mm is usually pathological.<sup>4-6</sup> If the pupil does not constrict normally in response to light, its constriction to a near target should be tested.

Testing for the presence of the relative afferent pupillary defect (RAPD) is the next step in a pupillary examination. Light is shone for 2-4 seconds in one eye and then quickly moved to the other eye. Normally, both pupils should remain the same size after each switch is made. If a dilation (even if it is very subtle) of the pupil receiving the switched light is noticed, and if the other pupil constricts when the light returns, RAPD is present in the eye with the pupillary dilation. RAPD can be quantified by using neutral density filters. Its presence indicates an asymmetrical optic neuropathy, which is almost

**Table 1: Eye disorders indicating the presence or absence of the relative afferent pupillary defect (RAPD)**

Disorder	RAPD—yes or no
Media opacity (cataract, even a very dense one)	No
Macular lesions	No or very subtle
Unilateral or asymmetrical optic neuropathy	Yes
Chiasmal lesion	Yes, if asymmetrical
Optic tract lesions	Yes (very subtle, contralateral)
Amblyopia	No or very subtle
Retinal lesions	No (unless lesion is very large, then subtle)
Psychogenic visual loss	No

always pathological. Table 1 lists various disorders and the expected associated presence of RAPD.

### Evaluation of a patient with anisocoria

In the presence of anisocoria, a simple algorithm based on the reaction of the pupils to a light stimulus can be useful in arriving at the correct diagnosis. If the reaction to light is normal (ie, both pupils constrict the same amount), anisocoria is either physiological or due to a defect in the sympathetic pathway (Horner syndrome). In this situation, the next step would be to perform pharmacological testing for Horner syndrome, using cocaine or apraclonidine. If the reaction to light is deficient in one pupil, a defect in the parasympathetic pathway or the iris sphincter is present (Figure 3).

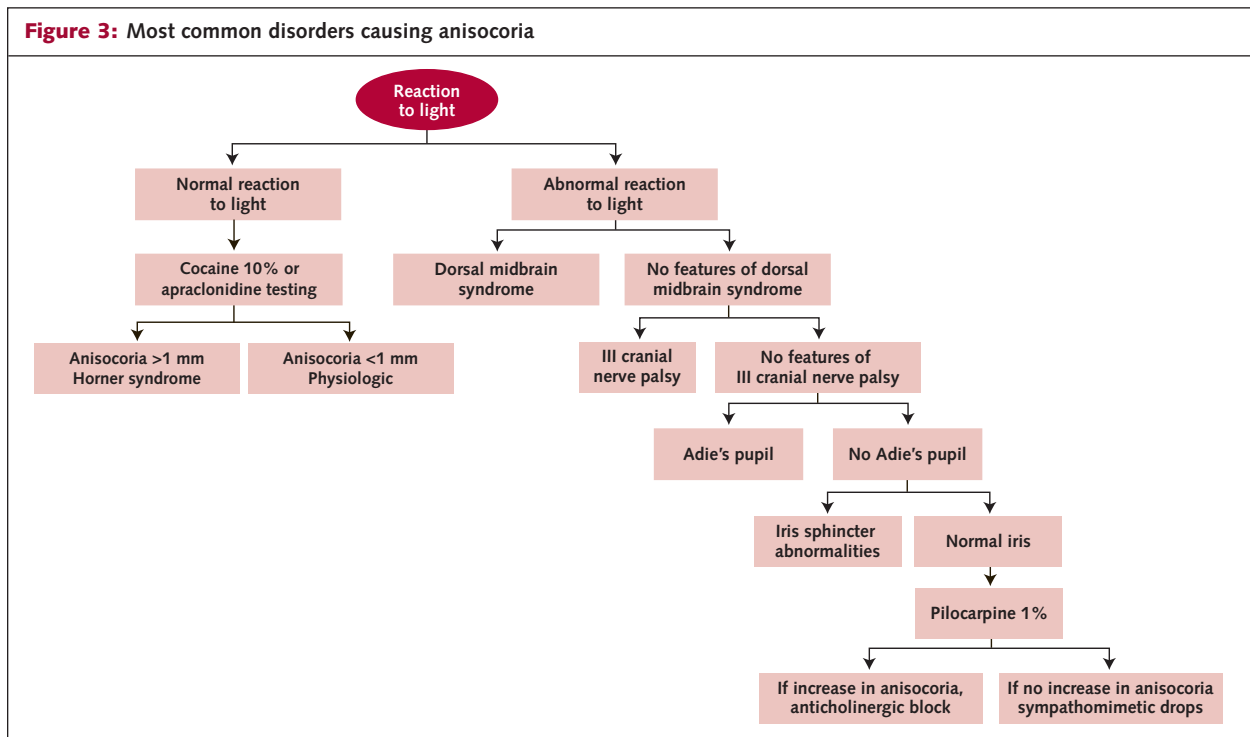
Another algorithm based on the evaluation of anisocoria in light and dim illumination is also frequently suggested. Using this scheme, the examiner measures the pupillary size in the light and then in the dark. If the anisocoria is greater in the dark, the abnormal pupil is the smaller one. If it is greater in the light, the larger pupil is abnormal. When the abnormal pupil is larger, abnormalities in the parasympathetic system (III nerve or ciliary ganglion) or in the iris sphincter are present. Presence of III nerve palsy features and iris sphincter abnormalities on slit-lamp examination should be sought and if none are present, testing with 0.13% topical pilocarpine should be carried out. If the pupil constricts in response to this test, Adie's pupil is diagnosed; if it does not, 1% pilocarpine is instilled. If the pupil does not constrict, pharmacological instillation of parasympathomimetic drops is the culprit.

The most common disorders causing anisocoria are described below.

### Horner syndrome

This disorder implies a disruption of the normal sympathetic innervations to the eye and ocular adnexa. The sympathetic innervation of the eye is complex as noted above and in Figure 2. Correctly diagnosing and investigating patients with Horner syndrome is of paramount importance because depending on the location of the damage to the sympathetic chain the etiology of Horner syndrome can vary from benign to life-threatening.

- *First-order lesions* are relatively uncommon. Brainstem or spinal-cord lesions are the usual



culprits; however, given the other associated deficits, these patients rarely present to the ophthalmologist.

- Most common *second-order neuron lesions* are caused by lung masses, thyroid lesions, or as a result of damage to the sympathetic pathway from the insertion of central lines in critically ill patients.
- *Third-order neuron lesions* can be the result of carotid-artery dissection, cavernous sinus lesions, and cluster headaches. However, it should be recognized that in many cases (up to 40% in one study), no identifiable cause would be found.<sup>7</sup>

Clinically, the familiar triad of Horner syndrome consists of anisocoria, mild ptosis, and occasionally anhidrosis (if the damage to the sympathetic pathway is before the carotid bifurcations). In patients with congenital Horner syndrome, iris heterochromia is usually present, where the iris is lighter in the dark irides and darker in the light ones on the affected side. All signs can be subtle and easy to miss; in particular, ptosis can be very mild and therefore should not be relied upon to exclude Horner syndrome. Anisocoria is more pronounced in the dark since sympathetic innervation of the pupil is usually unopposed in the dark and the difference between the normal and abnormal pupil becomes more obvious. Ptosis is either very mild or may not be present at all; the innervation of Müller muscle by the sympathetic system is responsible for only 2 mm of lid elevation. Sometimes reverse ptosis of the lower lid where sympathetic fibres innervate the Müller-muscle analogue can be observed as a slight drooping of the lid. A so-called "dilation lag" is another useful diagnostic feature of Horner syndrome, with the abnormal pupil taking longer to dilate than the normal pupil after dimming the lights. The test is performed in a dark room where a dim light is shone from below into both pupils. Room lights are switched on and off and the dilation time of each pupil is observed after switching off the room lights.

Definitive testing involves instillation of cocaine drops into both eyes and measuring the pupillary response. Cocaine blocks the reuptake of norepinephrine at the presynaptic junction; therefore, the amount of available norepinephrine at the synapse is increased, causing pupillary dilation. In pupils with abnormal sympathetic innervations, there is much less norepinephrine available for release and, therefore, the effect of cocaine on pupillary dilation is much less pronounced. Horner syndrome can be diagnosed if the difference in pupillary size is

$\geq 0.8$  mm 30 minutes after the instillation of 10% cocaine drops.<sup>8</sup>

Previously, a hydroxyamphetamine test was used to further localize the lesion location. Hydroxyamphetamine acts by releasing norepinephrine from the presynaptic neuron. In lesions of the third-order neurons, instillation of hydroxyamphetamine would have no effect on pupillary dilation, since the availability of norepinephrine at the presynaptic neuron would be very limited. However, in first- and second-order neuron lesions, anisocoria should reverse after hydroxyamphetamine drops. Currently hydroxyamphetamine is no longer commercially available and with the recent advances in neuroimaging this test has become obsolete.

Recently, apraclonidine has been used for diagnosing Horner syndrome. This is an alpha-adrenergic agonist that theoretically stimulates denervated and thus hypersensitive alpha-1 receptors in the pupillary dilator muscle causing the reversal of anisocoria.<sup>9</sup> In a study by Brown et al,<sup>10</sup> 1 drop of apraclonidine (1%) resulted in mydriasis of 1-4.5 mm in the affected pupil in all patients. Koc et al<sup>11</sup> demonstrated reversal of anisocoria after instillation of apraclonidine 1% in all 31 patients with confirmed Horner syndrome, causing a mean 2.4-mm dilation in the pupil with Horner syndrome and an average constriction of 0.14 mm in normal pupils.

After the diagnosis of Horner syndrome, the correct course of action should be established for each particular patient. If the onset of Horner syndrome is fairly recent, magnetic resonance imaging (MRI) and MR angiography (MRA) or a computed tomography (CT) and CT angiography (CTA) of the head and neck, as well as a chest X-ray, should be performed to rule out causes with potentially very severe consequences (carotid-artery dissection, neck and lung masses). CT and CTA are usually easier to obtain and require much less time to complete than MRI and MRA, but the downside is the relatively large dose of radiation exposure. Any patient with a painful Horner syndrome and any patient with Horner and other associated lesions (ie, sixth-nerve palsy or neurological deficits) requires emergency investigation and/or referral.

Carotid-artery dissection carries the highest risk of stroke in the 2 weeks after the onset of symptoms, and Horner syndrome is the presenting manifestation in almost 80% of patients.<sup>12,13</sup> Imaging should thus be performed urgently in these patients. Treatment with anticoagulation is controversial because no study has consistently demonstrated its benefits. Currently, a clinical trial is underway to determine whether treatment with

anticoagulation or antiplatelet therapy is beneficial in patients with carotid-artery dissection.<sup>14</sup>

### **Third-nerve palsy**

The third cranial nerve innervates levator palpebrae superior and all of the extraocular muscles except for the lateral rectus and superior oblique muscles. It also supplies parasympathetic innervation to the pupillary sphincter and ciliary body. Dysfunction of this nerve may affect any or all of these functions, depending on the location and etiology of the lesion. A patient with complete third-nerve palsy usually does not present a diagnostic challenge. Partial third-nerve palsies, however, can be difficult to recognize and diagnose and clinicians must keep this diagnosis in mind whenever a patient with ocular motility limitations, ptosis, and/or pupillary dysfunction is encountered.

Anatomically, the third cranial nerve can be divided into 5 distinct segments beginning from its origin in the rostral midbrain: the nuclear, fascicular, subarachnoid space, cavernous sinus, and orbital segments. Lesions in these different anatomical locations produce distinct clinical signs.

- Nuclear lesions manifest as bilateral ptosis and ipsilateral elevation deficits due to the bilateral projections from the levator palpebrae sub-nucleus and contralateral projections from the superior rectus nucleus.
- Fascicular lesions (affecting the fibres of the nerve as they run through the midbrain substance after exiting the nucleus) in addition to producing ipsilateral third-nerve palsy can also cause neurological signs due to the involvement of the red nucleus, and the corticospinal and cerebellar tracts (eg, tremor, contralateral hemiplegia or cerebellar ataxia).
- In the subarachnoid space, the nerve travels inferior to the posterior communicating artery along its course toward the internal carotid artery. The junction of the posterior communicating and internal carotid arteries is a common location for aneurysms that can compress the third-nerve fibres. Since pupillary fibres run on the outer surface of the nerve, a dilated pupil is frequently the first manifestation of this life-threatening condition.
- Lesions of the nerve in the cavernous sinus usually produce other cranial-nerve deficits, since cranial nerves IV, V1, V2, and VI all traverse the cavernous sinus.
- Orbital lesions tend to produce partial palsies because the nerve divides into superior and inferior divisions at the anterior cavernous sinus or at the superior orbital fissure. Thus, lesions of

the inferior division (innervating the medial and inferior rectus and inferior oblique muscles, as well as pupillary sphincter muscles) produce infero- and adduction deficits and pupillary dilation. Lesions of the superior branch produce supraduction deficits and ptosis.

### **Complete pupillary-sparing third-nerve palsy**

The most common cause for this disorder is ischemia. The disorder manifests as complete ptosis, appropriate motility deficits, but normal pupillary function. Rarer etiologies include trauma, giant-cell arteritis, and infiltrative lesions. A recent study by Kupersmith et al<sup>15</sup> found that complete pupillary sparing III cranial nerve palsy in adult patients aged >50 years with atherosclerotic risk factors is the only situation where neuroimaging is not required. Patients should be observed closely for the first week for the development of pupillary involvement. If motility and ptosis do not begin to improve after 6-8 weeks or if aberrant regeneration develops, MRI/MRA should be performed.

### **Complete or partial pupillary-involving third-nerve palsies**

Any pupillary involvement warrants an urgent imaging study (MRI/MRA or CT/CTA) to rule out an aneurysm at the junction of the posterior communicating and internal carotid arteries.

### **Partial pupillary-sparing third-nerve palsy**

In these cases aneurysms can be a culprit, therefore, neuroimaging is required. Other etiologies may include ischemia, trauma, neoplasms, demyelination, and infections. Patients with isolated pupillary dilation but no motility disturbance do not require imaging, since isolated mydriasis is not caused by third-nerve palsies.

### **Adie's tonic pupil**

This is an idiopathic disorder that affects the parasympathetic innervations of the pupil. Frequently, deep-tendon reflexes are absent and the condition is then termed Adie syndrome. Patients notice a dilated pupil on the affected eye due to the unopposed action of the sympathetic system. On slit-lamp examination, typical segmental or "vermiform" (worm-like) constriction of the pupil is seen. Light-near dissociation is another common feature and is due to the aberrant regeneration of the autonomic fibres. There are 30 times more fibres innervating the ciliary body than there are those innervating the pupillary sphincter muscle. As a result, there is a much higher chance of the regrowth of pupillary fibres becoming misdirected to the ciliary body.

This condition can be proven pharmacologically by the instillation of a very weak solution of pilocarpine (0.1%). The affected pupil will demonstrate cholinergic hypersensitivity by constricting, whereas the normal pupil will not. With time, tonic pupils become smaller (mnemonic "Little Old Addies"). The condition is completely benign and, since the clinical presentation is usually classic, no further testing or investigations are necessary.

## Conclusion

Pupillary physiology is complex but familiarity with the anatomical pathways responsible for pupillary constriction and dilation will enable a clinician to evaluate and manage patients who present with pupillary abnormalities. This is particularly important as some life-threatening disorders (eg, carotid artery dissection, carotid artery aneurysms) can present with pupillary signs as their first manifestation and the ophthalmologist may be the first physician to whom these patients present. These signs must be correctly recognized and managed to optimize the potential for recovery in these patients.

---

*Dr. Margolin is an Assistant Professor at the Mount Sinai Hospital and Department of Ophthalmology and Visual Sciences at the University of Toronto.*

*Dr. Chan is a fourth-year ophthalmology resident.*

---

## References

1. Cibis GW, et al. *Fundamentals and Principles of Ophthalmology. Basic and Clinical Science Course*. American Academy of Ophthalmology (AAO): San Francisco, 2006. Chapter 3, pp. 110-111.
2. Kline LB, Bajandas FJ. *Neuroophthalmology Review Manual*. 5<sup>th</sup> ed. Slack Inc; New Jersey: 2004. Chapter 8, pp. 125-137.
3. Wong AMF. *Eye Movement Disorders*. New York, NY: Oxford; 2008.
4. Lam BL, Thompson HS, Walls RC. Effect of light on the prevalence of simple anisocoria. *Ophthalmology*. 1996;103(5):790-793.
5. Lam BL, Thompson HS, Corbett JJ. The prevalence of simple anisocoria. *Am J Ophthalmol*. 1987;104(1):69-73.
6. Burde RM, Savino PJ, Trobe JD. *Clinical Decisions in Neuroophthalmology*. 3<sup>rd</sup> ed. Mosby: St. Louis, 2002. Chapter 11, pp. 247-271.
7. Maloney WF, Younger BR, Moyer NJ. Evaluation of the causes and accuracy of pharmacologic localization in Horner's syndrome. *Am J Ophthalmol*. 1980;90(3):394-402.
8. Kardon, RH, Denison CE, Brown CK, Thompson HS. Critical evaluation of the cocaine test in the diagnosis of Horner's syndrome. *Arch Ophthalmol*. 1990;108(3):384-387.
9. Morales J, Brown SM, Abdul-Rahim AS, Crosson CE. Ocular effects of apraclonidine in Horner syndrome. *Arch Ophthalmol*. 2000;118(7):951-954.
10. Brown SM, Aouchiche R, Freedman KA. The utility of 0.5% apraclonidine in the diagnosis of Horner syndrome. *Arch Ophthalmol*. 2003; 121(8):1201-1203.
11. Koc F, Kavuncu S, Kansu T, Acaroglu G, Firat E. The sensitivity and specificity of 0.5% apraclonidine in the diagnosis of oculomotoric paresis. *Br J Ophthalmol*. 2005;89(11):1442-1444.
12. Caplan LR, Biousse V. Cervicocranial arterial dissections. *J Neuro-ophthalmol*. 2004;24(4):299-305.
13. Arauz A, Hoyos L, Espinoza C, Cantú C, Barinagarrementeria F, Román G. Dissection of cervical arteries: Long-term follow-up study of 130 consecutive cases. *Cerebrovasc Dis*. 2006;22(2-3):150-4.
14. Antiplatelet therapy vs. anticoagulation in cervical artery dissection: rationale and design of the Cervical Artery Dissection in Stroke Study (CADISS). *Int J Stroke*. 2007;2(4):292-296.
15. Kupersmith MJ, Heller G, Cox TA. Magnetic resonance angiography and clinical evaluation of third nerve palsies and posterior communicating artery aneurysms. *J Neurosurg*. 2006;105(2):228-234.

## University of Toronto Department of Ophthalmology and Vision Sciences

### Upcoming events

- 5–6 December 2008** **Walter Wright Day – Course Director, Dr. Baseer Khan**  
Toronto International Congress Centre
- 18 December 2008** **Visiting Professor, Dr. Phil Hooper,**  
University of Western Ontario  
Uveitis
- 31 January 2009** **Toronto Cataract Course**  
Contact U of T CME Office:  
416-978-2719
- 4 April 2009** **Neuro-Vascular Protection  
in Diabetes meeting**  
Pantages Suites Hotel and Spa  
Course Director, Dr. Shelley Boyd
- 24 April 2009** **Jack Crawford Day**  
Contact: Karen Martin  
416-813-8942 or  
karen.martin@sickkids.ca

### For more information:

Office of Continuing Education and Professional Development  
Faculty of Medicine, University of Toronto  
Phone: 416.978.2719/1.888.512.8173  
E-mail: help-OPT0802@cmeteronto.ca  
<http://events.cmeteronto.ca/website/index/OPT0802>

---

**Disclosure Statement:** Drs. Margolin and Chan have stated that they have no disclosures to announce in association with the contents of this issue.

*The authors are grateful to Dr. Jonathan Trobe for allowing them to use the modified version of the anisocoria work-up table conceived by him in our publication*

Change of address notices and requests for subscriptions for *Ophthalmology Rounds* are to be sent by mail to P.O. Box 310, Station H, Montreal, Quebec H3G 2K8 or by fax to (514) 932-5114 or by e-mail to [info@snellmedical.com](mailto:info@snellmedical.com). Please reference *Ophthalmology Rounds* in your correspondence. Undeliverable copies are to be sent to the address above. Publications Post #40032303

---

This publication is made possible by an unrestricted educational grant from

# Novartis Ophthalmics

---

© 2008 Department of Ophthalmology and Vision Sciences, Faculty of Medicine, University of Toronto, which is solely responsible for the contents. Publisher: SNELL Medical Communication Inc. in cooperation with the Department of Ophthalmology and Vision Sciences, Faculty of Medicine, University of Toronto. <sup>®</sup>*Ophthalmology Rounds* is a registered trademark of SNELL Medical Communication Inc. All rights reserved. The administration of any therapies discussed or referred to in *Ophthalmology Rounds* should always be consistent with the approved prescribing information in Canada. SNELL Medical Communication Inc. is committed to the development of superior Continuing Medical Education.