

Ophthalmology & Vision Sciences
UNIVERSITY OF TORONTO

Refractive Surgery: Today and the Future

RAYMOND STEIN, MD, FRCSC, AND REBECCA STEIN, BSc, MBChB

Technologies and techniques continue to evolve in the correction of myopia, hyperopia, astigmatism, and presbyopia. Patients are increasingly interested in spectacle or contact lens independence. Clinicians need to understand today's options for vision correction. This issue of *Ophthalmology Rounds* provides an overview of this exciting area of clinical advancements and research.

With every surgical innovation, it is important to critically evaluate the outcomes and safety with long-term data. We need to be cautious with any new technology, as many refractive procedures have been abandoned due to lack of efficacy or late complications (Table 1).

Patients typically have high expectations with the available technology. They want their post-operative uncorrected visual acuity (UCVA) to be equal or greater to their preoperative best-spectacle corrected VA (BCVA). The role of the clinician is to evaluate the patient and the ocular health to determine if they are good candidates for any refractive procedure. Preoperative findings will guide the surgeon in recommending specific refractive options (Table 2). To determine the preferred surgical option, we can differentiate higher-order aberrations of the cornea versus the lens. Advanced wavefront units allow measurement of total higher-order aberrations of the eye, which can be differentiated into those from the cornea versus the lens. In patients with significant higher-order aberrations of the lens, a refractive lens exchange would be the treatment of choice to improve the overall quality of vision.

Laser Vision Correction

Laser-assisted in situ keratomileusis (LASIK) and photorefractive keratectomy (PRK)

More than 35 million LASIK and PRK procedures have been performed worldwide with reported improvement in outcomes and safety.¹ Significant advances over the past 30 years in excimer laser technology include improved nomograms, flying spot lasers with smoother ablations, more accurate trackers, larger optical zones, aspheric curves, and customized treatments that reduce not only refractive errors but other optical aberrations of the eye.

PRK provides excellent outcomes similar to LASIK. Although some surgeons prefer PRK over LASIK because of the reduced risk of corneal ectasia, most offer LASIK first because of quicker post-operative healing. Surgeons typically recommend PRK when the cornea is thin, mildly irregular, or has evidence of epithelial basement membrane dystrophy. PRK may also be preferred if the patient has a narrow fissure that complicates flap creation or is at higher risk of flap subluxation due to factors such as an occupation or sporting activity. PRK improves quality of day and night vision and maintenance of corneal clarity secondary to the use of larger optical zones, flying spot lasers that create a smoother ablation, adjunctive use of mitomycin C to reduce the risk of corneal haze, and custom treatments such as topography- and wavefront-guided ablations and wavefront-optimized treatments. Custom ablation with PRK offers the same refractive results as small-incision lenticule extraction (SMILE) but with fewer induced higher-order aberrations.² Patients are relatively comfortable following PRK with application of sterile ice to the surface of the cornea, bandage soft contact lenses, and nonsteroidal drops.

LASIK is among the most frequently performed and successful medical procedures.^{3,4} With proper preoperative screening, visual outcomes are excellent with a low complication rate. In North America, femtosecond lasers for creation of the corneal flap have generally replaced blade microkeratomes. Advances in femtosecond technology have shown predictable flap thickness and the ability to customize the diameter, location, hinge, and edge profile of the LASIK flap. In the rare event of suction loss with a femtosecond laser, the suction ring can be reapplied and the procedure completed. With suction loss using a mechanical microkeratome, the procedure is aborted and the patient must return a few months later for PRK.

Department of Ophthalmology and Vision Sciences

Sherif El-Defrawy, MD

Professor and Chair

Jeffrey J. Hurwitz, MD

Editor, *Ophthalmology Rounds*

Valerie Wallace, PhD

Director of Research

The Hospital for Sick Children

Agnes Wong, MD

Ophthalmologist-in-Chief

Mount Sinai Hospital

David B. Yan, MD

Ophthalmologist-in-Chief

Princess Margaret Hospital

(Eye Tumour Clinic)

Hatem Krema, MD

Director, Ocular Oncology Service

St. Michael's Hospital

David Wong, MD

Ophthalmologist-in-Chief

The John and Liz Tory Eye Centre Sunnybrook Health Sciences Centre

Peter J. Kertes, MD

Ophthalmologist-in-Chief

University Health Network

Toronto Western Hospital Division

Robert G. Devenyi, MD

Ophthalmologist-in-Chief

Kensington Eye Institute

Sherif El-Defrawy, MD

Ophthalmologist-in-Chief

Department of Ophthalmology and Vision Sciences,

Faculty of Medicine,

University of Toronto,

60 Murray St.

Suite 1-003

Toronto, ON M5G 1X5

The editorial content of *Ophthalmology Rounds* is determined solely by the Department of Ophthalmology and Vision Sciences, Faculty of Medicine, University of Toronto

NEW!
READER FORUM

Please visit www.ophtalmologyrounds.ca and follow the Comments link to submit a comment on a recent issue and to read what your colleagues are contributing to the dialogue.

Table 1. Current and historical refractive procedures.				
Refractive Procedures	Myopia	Hyperopia	Presbyopia	Macular Degeneration
Current	<ul style="list-style-type: none"> • PRK • LASIK • SMILE • Phakic IOL • RLE 	<ul style="list-style-type: none"> • PRK • LASIK • Phakic IOL • RLE 	<ul style="list-style-type: none"> • EDOF IOLs • Multifocal IOLs • Accommodating IOLs • Corneal inlays • Monovision (PRK, LASIK, SMILE, RLE) • Monofocal IOL (induced spherical aberration) 	<ul style="list-style-type: none"> • Corneal photovitrification
Past	<ul style="list-style-type: none"> • Keratomileusis • ALK • Epikeratophakia • Radial keratotomy • Corneal rings 	<ul style="list-style-type: none"> • Epikeratophakia • Hexagonal keratotomy • Thermal keratoplasty • Lasso suture 	<ul style="list-style-type: none"> • Scleral ablations • Scleral inserts • Corneal shrinkage • Intracor • Raindrop inlay 	<ul style="list-style-type: none"> • Rheophoresis

PRK = photorefractive keratectomy; LASIK = laser-assisted *in situ* keratomileusis; SMILE = small-incision lenticule extraction; IOL = intraocular lens; RLE = refractive lens exchange; ALK = automated lamellar keratoplasty; EDOF = extended depth-of-focus

In a large LASIK clinical review (97 papers; 67 893 eyes) from 2008–2015, 90.8% of eyes achieved a distance UCVA $\geq 20/20$ and 99.5% achieved $\geq 20/40$.⁵ The spherical equivalent refraction was within ± 0.50 D of target in 90.9% of eyes and within ± 1.00 D of target in 98.6%. These outcomes were superior to earlier reports, which reflect further advances in hardware and software of the lasers, surgical techniques, and improved patient selection. Loss of 2 or more lines of corrected distance visual acuity (CDVA) was 0.61%, less than one half the number of eyes that had an increase in CDVA of 2 lines or more (1.45%). The more advanced treatments (topography- and wavefront-guided or wavefront-optimized) allowed for an UDVA of nearly a full line better than in eyes with conventional treatments. Most treatments in the review were for myopia and myopic astigmatism; hyperopic treatments represented 3% of cases.⁵ A ≥ 2 -line CDVA loss was more common in hyperopic than myopic treatments (2.13% versus 0.95%); this may be related to more sensitive centration of the hyperopic treatment, which has been shown to be best centered on line of sight versus the centre of the pupil. Hyperopic treatments are also associated with a greater risk of regression versus myopic treatments.

The most significant long-term complication of LASIK is corneal ectasia (incidence $\sim 0.03\%$).⁶ The risk has been lowered by improved preoperative detection of forme-fruste keratoconus, keratoconus, and pellucid marginal degeneration with elevation tomography that detects elevation

abnormalities on the anterior and posterior corneal surfaces.⁷ Other factors accounting for improved LASIK outcomes include avoidance of surgery on thin corneas or those with high myopia, creation of thinner corneal flaps, and leaving a thicker residual bed underneath the flap.^{8,9} The presently preferred treatment of corneal ectasia is with corneal crosslinking and possibly topography-guided PRK or an intracorneal ring to reduce irregular astigmatism.¹⁰ Early ectasia detection and treatment can limit corneal irregularity and provide better VA.

Further research in tracking devices, torsional alignment, the ideal centration of ablations, an understanding of the biomechanical properties of the cornea, and medications or adjunctive procedures to modulate wound healing will enhance our outcomes and patient safety for all laser vision correction procedures.

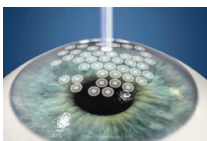
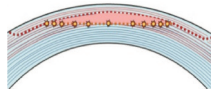
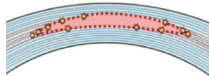
SMILE procedure

SMILE is a new method of intrastromal keratomileusis in which a femtosecond laser is used to create 2 cuts within the cornea and 1 small superficial cut.^{11,12} A lenticule is produced of a specific shape and thickness, and is pulled out mechanically through a 2–3 mm corneal incision. SMILE is an alternative refractive procedure for the correction of myopia and myopic astigmatism. Recent studies have validated the efficacy and safety.¹² Table 3 presents a comparison of LASIK, PRK, and SMILE.

Table 2. Refractive options based on clinical findings.	
Clinical Finding	Refractive Options
• Thin cornea and/or high myopia	• PRK, phakic IOL
• High hyperopia (>3 D)	• RLE, phakic IOL
• Forme-fruste keratoconus, keratoconus, pellucid marginal degeneration, ectasia	• PRK, topography-guided PRK, Intacs, phakic IOL, \pm CXL
• Lenticular changes	• RLE, early cataract surgery
• Higher-order lens aberrations	• RLE
• Predicted postoperative curvature < 32 or > 50 D	• RLE, phakic IOL
• Presbyopia	• Monovision (with PRK, LASIK, SMILE), RLE, corneal inlay
• AMD or other forms of central vision loss	• Corneal photovitrification

CXL = corneal cross-linking; AMD = age-related macular degeneration

Table 3. Comparison of PRK, LASIK, and SMILE.

	PRK	LASIK	SMILE
Technique of Vision Correction			
Health Canada Approval	1990	1994	2015
Generation of equipment	5th Generation	5th Generation	1st Generation
Type of treatment	Laser photoablation	Laser photoablation	Laser photodisruption
Precision	0.12 µm/pulse	0.12 µm/pulse	2-3 µm/pulse
Smoothness of refractive correction	Smooth excimer ablation	Smooth excimer ablation	Femtosecond (rougher than excimer)
Blade-free	Yes	Yes	Yes
Type of laser	Excimer	Femtosecond and excimer	Femtosecond
Myopic correction: Low (<3 D)	Yes	Yes	Difficult if thin lenticule
Higher (>3 D)	Yes	Yes	Yes
Myopic astigmatic correction	Yes	Yes	Yes difficult if spheroequivalent <3 D
Hyperopic correction	Yes	Yes	Future
Hyperopic astigmatic correction	Yes	Yes	Future
Topography-guided treatments	Yes	Yes	Future
Wavefront-guided treatments	Yes	Yes	Future
Optical centration adjustment	Yes	Yes	Future
Cyclotorsion adjustment	Yes	Yes	Future
Return of best UCVA ^{2,14-16}	Slowest	Fastest	Slower than LASIK
Best UCVA ^{2,14-16}	Superior (custom ablation)	Superior (custom ablation)	Good (non-customized)
Higher-order aberrations ^{2,14-16}	Less (custom ablation)	Less (custom ablation)	Highest (non-customized)
Enhancements	Yes	Yes	More difficult
Dry eyes: <6 month ¹⁸ >6 months ¹⁸	Increase (typically mild) Same	Increase (typically mild) Same	Increase (less than PRK or LASIK) Same
Risk of ectasia: low myopia ²⁵ high myopia ²⁵	Lowest Lowest	Low Low (similar to SMILE)	Greater (more tissue removed) Low (similar to LASIK)

UCVA = uncorrected visual acuity

SMILE is currently reserved for myopia and myopic astigmatism. Enhancement procedures tend to be with PRK, although some recent evidence supports LASIK to correct residual refractive errors.¹³ Current limitations of first-generation SMILE versus LASIK include difficulty in performing low myopic corrections (<3 D) because of a thin and fragile lenticule, lack of effect on hyperopia or hyperopic astigmatism, inability to perform topography- or wavefront-guided treatment, less-smooth cuts with femtosecond laser than excimer, lack of optical centration adjustment when the suction device is placed on the eye, no cyclotorsion compensation, slower return of UCVA, and inferior improvement in best UCVA compared to custom treatments.¹⁴⁻¹⁶ Since the overlying cap in SMILE is adherent there is essentially no risk of subluxation, although this is rare after LASIK.¹⁷ Future refinements in the hardware of the laser technology, and software design will improve the outcomes of the SMILE procedure.

A recent meta-analysis compared SMILE (291 eyes) with femtosecond LASIK (FS-LASIK; 277 eyes) for correcting myopia in patients with dry eye.¹⁸ The authors concluded that dry eye occurs transiently after both SMILE and LASIK, and although there are some early postoperative advantages of SMILE, there is no long-term superiority over FS-LASIK in

terms of tear breakup, quantity of tears, or subjective symptoms. Previous meta-analyses found a lower risk of post-operative dry eye with SMILE.^{19,20}

Reduction in corneal sensation occurs in both the creation of the LASIK flap and subsequent excimer ablation as well as the SMILE procedure. Randomized controlled studies suggest that there is no increased risk of dry eye secondary to corneal neuralgia;^{20,21} however, other reports find an association.^{22,23} One meta-analysis, reported that corneal sensitivity in the SMILE group recovered faster than in the FS-LASIK group during the first three months postoperatively, but that recovery was similar six months after surgery.²⁴

Corneal biomechanical properties are critical in laser vision correction to allow stability of the refractive correction and prevent corneal ectasia. Removal of corneal tissue by both SMILE and LASIK reduces corneal tensile strength and is directly correlated with the extent of a myopic ablation.²⁵ SMILE appears to result in a greater reduction of tensile strength in lower myopic corrections, since more tissue is removed, and a similar reduction in higher corrections.²⁵ However, finite-element models, mathematical analysis, and cadaver cornea experiments suggest that SMILE may preserve corneal biomechanical properties better

than LASIK.^{26,27} Since iatrogenic ectasia is a rare complication, it is recommended that the indications and exclusion criteria for SMILE should follow the same guidelines as LASIK.

Phakic Intraocular Lenses (IOLs)

Phakic IOL insertion is the procedure of choice to treat high degrees of myopia and astigmatism, especially in nonpresbyopic patients with clear crystalline lenses. Unlike with laser vision correction, the procedure is reversible as no tissue is removed, and there is essentially no induced dry eye. The 2 locations for the phakic IOL include the anterior chamber such as iris-claw intraocular implantation or posterior chamber. Anterior-chamber iris-supported phakic IOLs have been associated with an increased corneal endothelial cell loss compared to posterior-chamber phakic IOLs.²⁸

Implantable contact lenses (ICLs) have shown excellent outcomes and high patient satisfaction rates.²⁹⁻³¹ The material is a collamer substance that offers ultraviolet (UV) protection. The EVO Visian ICL (Staar Surgical) is the latest innovation in which a microscopic hole has been placed in the optic of the lens to prevent pupillary block glaucoma (Figure 1). This small hole obviates the need for a preoperative yttrium aluminum garnet (YAG) laser iridotomy in which 2 openings were created. The hole can also decrease the risk of an anterior cortical cataract by enhancing fluid flow in the anterior chamber. Long-term data with non-EVO design has shown a low incidence of cataracts.³² The EVO Visian ICL is available for the correction of up to 20 D of myopia and 6 D of astigmatism. A non-EVO ICL is available for the correction of hyperopia; however, many hyperopes are unsuitable candidates because of narrow anterior chambers. One special indication for the hyperopic ICL is patients who have had radial keratotomy since these are myopic eyes with deeper anterior chambers.

An extended depth-of-focus (EDOF) ICL is undergoing clinical trials. The lens has the potential to serve the needs of young presbyopic patients who desire a full range of vision without significant intraocular higher-order aberrations.

Refractive Lens Exchange (RLE)

RLE has shown a recent increase in use secondary to advances and safety of microincisional phacoemulsification, more accurate optical biometry, improved IOL formulas, and advances in IOL designs.^{33,34} It is the preferred procedure for patients with early lenticular changes, significant higher-order lens aberrations, high hyperopia, high myopia in eyes unsuitable for a phakic implant because of a shallow ante-

rior chamber or low endothelial cell count, and presbyopes desiring improvement in distance, intermediate, and near vision. Advances in multifocal implants or the technique of monovision have allowed presbyopic patients to achieve a full range of vision. Monofocal implants are available to reduce spherical aberration and correct astigmatism. A larger range of IOL powers are available, including high negative powers for high myopes and high positive powers for high hyperopes. An advantage of RLE is that it eliminates the need for future cataract surgery.

The “holy grail” in ophthalmology is the correction of presbyopia. Many factors are responsible for the creation of presbyopia (Figure 2), but increased lens rigidity appears to be the principal cause. Most surgical corrections of presbyopia employ an RLE with a multifocal IOL.

As with all refractive procedures, the risks and benefits of surgery must be discussed with the patient. Multifocal IOLs may be associated with glare, halos, and loss of contrast sensitivity. Symptoms from optical aberrations generally improve with time secondary to neuroadaptation.^{35,36} Similar to cataract surgery, RLE can be associated with vision-threatening complications, such as chronic cystoid macular edema, endophthalmitis, or retinal detachment. A detached retina is the main concern in younger patients who are highly myopic with long axial lengths that have not undergone a complete posterior vitreous detachment.³⁷ Reported outcomes of RLE are similar in young versus older presbyopes with respect to visual and refractive outcomes, complication rates, and patient-reported satisfaction.³⁸

Almost 75% of patients who undergo lens-based surgery have ≥ 0.5 D astigmatism.³⁹ A residual astigmatism ≥ 0.75 D affects visual function and patient satisfaction.⁴⁰ Toric implants are more effective at reducing astigmatism compared with spherical implants and limbal relaxing incisions.³⁹ IOL formulas that empirically account for the posterior corneal curvature to determine the total corneal astigmatism (eg, Barrett Toric formula) have resulted in more accurate postoperative results.⁴⁰ Advances in actual measurements of the posterior corneal curvature are improving with devices such as the Cassini and IOLMaster 700.⁴¹ At the time of this writing there are conflicting reports as to whether these devices at this stage of development are more accurate than empirical measurements.

Patients who are presbyopic and who had previous laser vision correction are often motivated to enhance their intermediate and near vision, and often fine-tune their distance vision. Multifocal implants are often popular with these patients to provide full range of vision. Determination of the

Figure 1. EVO Visian implantable contact lens (Staar Surgical) with central opening in the optic that obviates the need for iridotomies. Markings on the optic are for toric alignment.

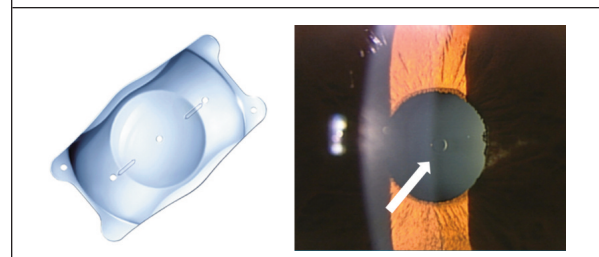


Figure 2. Etiology of presbyopia with increased lens rigidity as the primary cause.

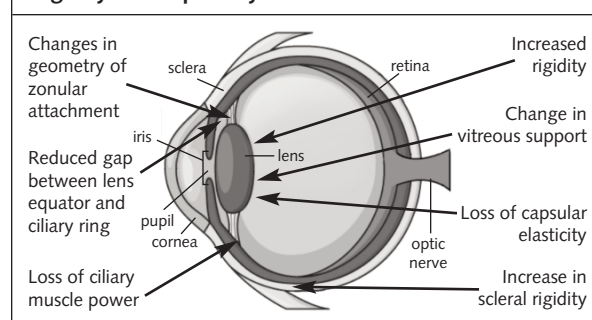


Table 4. Most commonly used presbyopic IOLs in Canada

	Symfony	PanOptix	FineVision	AT LISA
Presbyopic mechanism	Extended-depth of Focus	Trifocal	Trifocal	Trifocal
Material	Hydrophobic acrylate	Hydrophobic acrylate	Hydrophilic acrylate	Hydrophilic acrylate
Optic/diameter	6.0 mm/13.0 mm	6.0 mm/13.0 mm	6.15 mm/10.75 mm	6.0 mm/11.0 mm
Profile	Posterior achromatic diffractive	Non-apodized	2 apodized diffractive profiles	Diffractive profile using smooth steps
Intermediate	1.75 D add	2.17 D add	1.75 D add	1.66 D add
Near		3.25 D add	3.5 D add	3.33 D add
Spherical power	+5 to +34 D	+6 to +34 D	+10 to +34 D	0 to +32 D
Toric availability	Yes	Yes	Yes (special access)	Yes
Light distribution	Pupil independent	Less dependent on pupil size	Pupil dependent	Pupil independent
Comment	Good distance and intermediate vision but may have limited near vision unless mini-mono is performed.	Good distance, intermediate, and near vision.	Good distance, intermediate, and near vision.	Good distance, intermediate, and near vision.
	Halos tend to improve but may not resolve completely.			

ideal IOL power is often difficult, but has improved with use of the Barrett True-K formula for prior LASIK or PRK. In the future, the ability to accurately measure the total corneal astigmatism and axis by evaluating both the anterior and posterior corneal surface will be the technique of choice.

Today, surgeons can choose from an ever-increasing number of monofocal, toric, multifocal, and accommodative IOL options to meet the needs of their patients. Lens-based procedures such as refractive lens exchange continue to be the most accepted procedure to correct presbyopia (Table 4).

EDOF IOLs

EDOF IOLs tend to produce less glare and halos or loss of contrast compared to multifocals.⁴² They provide good uncorrected distance and intermediate vision; however, near vision is better with multifocal implants. Surgeons employing this type of lens tend to use a technique of micro-monovision in which the EDOF IOL is placed in the dominant eye and the other eye is left mildly myopic to enhance reading.

Multifocal IOLs

Among the most commonly used multifocal implants in Canada are the FineVision Trifocal (PhysIOL), PanOptix IOL (Alcon), and AT Lisa Trifocal (Zeiss). Glare and halos may occur especially in scotopic conditions; however, this tends to improve with time because of neuroadaptation. Trifocal implants provide better intermediate vision with fewer side effects by utilizing diffraction and asymmetric light distribution. It is valuable to measure angle kappa preoperatively since patients with a large positive angle kappa may not be able to tolerate multifocals because of the difference in their line of sight and the centre of the optic.

Segmented bifocal IOLs

The rotationally asymmetric segmented bifocal IOLs with sector-shaped near vision provides 2 focus zones for distance or for reading. Implants in this category are the LENTIS Mplus and Mplus X (Oculentis), and SBL-3 (Lenstec).^{43,44} Similar to multifocal implants, the patients may


have glare especially at night or in the presence of a residual refractive error. Refractions are more difficult, as patients will have refractive errors through the distance optic and the segmented bifocal.

Accommodating IOLs

Accommodative IOLs have had limited success in providing satisfactory near vision. These lenses include the Crystalens AO (Bausch + Lomb), Tetraflex (Lenstec) and the dual-optic IOL such as Synchrony (AMO).

Future accommodative IOLs in design or clinical study may offer patients the full range of vision without glare or halos, or quality of vision issues. The FluidVision IOL (PowerVision), currently in clinical trials, allows the quantity of fluid within the optic to increase or decrease, which changes the accommodative power (Figure 3).⁴⁵ With the accommodative response, fluid is displaced centrally into the lens, which expands the central membrane of the optic and facilitates near vision, with relaxation of the ciliary muscle, fluid returns to the periphery, and distance vision is created. The lens has been studied outside of North America with reports of accommodative amplitude of up to 3-4 D with 3 years of follow-up.⁴⁵ The Sapphire IOL (ELENZA) uses

Figure 3. FluidVision IOL (PowerVision) is inserted in the capsular bag. Accommodative effort results in changes in optic power from fluid flow to the central portion of the lens, which increases the power of the lens to enhance near vision. Image used with permission.



nanotechnology and advanced electronics to adjust the focus of the implant in response to pupillary changes. Utilizing artificial intelligence to differentiate between light stimulation and accommodation by sensing the speed and amplitude of the pupillary responses, the implant can provide quality of near vision.⁴⁶

A few sulcus-implanted accommodative IOLs are under clinical study. The DynaCurve IOL (NuLens) changes curvature in response to accommodation from a collapsed bag-zonular complex; this change activates a piston that induces a gel component to bulge and alter an anterior flexible membrane (Figure 4).⁴⁵ The optical power of the IOL will increase depending on the magnitude of the silicone bulge due to the contraction of the ciliary muscle. Early clinical studies improved near vision by up to 3.8 lines; however, 60% of eyes had significant capsular opacification that required a YAG capsulotomy.⁴⁵ The Lumina lens (AkkoLens/Oculentis) is also implanted in the ciliary sulcus; it has 2 optical elements that move with ciliary muscle contraction, one on top of the other, producing accommodation.⁴⁵ These elements provide a fixed optical power with anterior element providing 5 D and the posterior providing 10–25 D. The lens can be inserted through a 2.8–3.0-mm incision. A 12-month clinical trial showed significantly enhanced near vision compared to a monofocal IOL and with similar contrast sensitivity.⁴⁵

Small-aperture IOLs

Small-aperture IOLs can extend the depth of focus (Figure 5). These IOLs are especially effective in patients with significant higher-order aberrations such as those post-RK, keratoconus, or any other irregular corneal surface.^{47–49} The IC-8 IOL (AcuFocus) is a monofocal IOL similar to the KAMRA corneal inlay that utilizes the pinhole design to enhance the depth of focus. It has a 1.36-mm central aperture and a surrounding opaque area of 3.23 mm. The IC-8 IOL is inserted into the capsular bag. Clinical results have shown good distance, intermediate, and near vision, especially when targeting up to -0.75 D of myopia. The XtraFocus Pinhole implant (Morcher) is a small-aperture sulcus implant of black acrylic with a central opening. This lens is inserted

Figure 4. Dyna-Curve IOL (NuLens) is inserted in the ciliary sulcus with an intact capsular membrane. Accommodative effort pushes a gel centrally, which increases the optic power by bulging of an anterior flexible membrane to provide near vision.

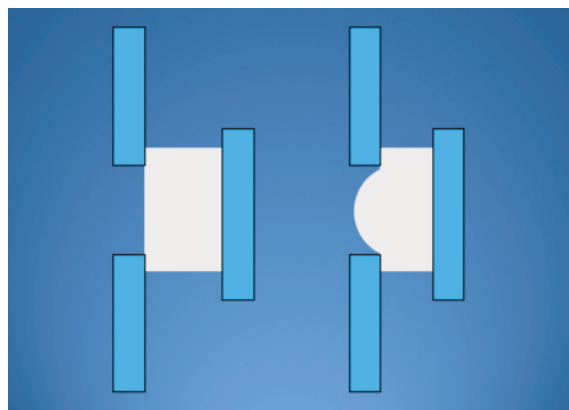



Figure 5. Small-aperture IOLs can extend the depth of focus and reduce higher-order aberrations by a small central clear area of the optic in which peripheral light is reduced. Left: IC-8 IOL (AcuFocus) for insertion in the capsular bag. Right: XtraFocus Pinhole implant (Morcher) for insertion in the ciliary sulcus. Images used with permission.



in the sulcus in pseudophakic eyes. It is especially effective in patients with unsatisfactory quality of vision despite lens implant surgery because of significant corneal aberrations.⁴⁹

Light-adjustable IOL

The light-adjustable IOL will be available in the future. This is a photosensitive silicone material that can be adjusted postoperatively with UV light to refine the outcome.^{50,51} After the standard IOL measurements and surgical procedure is performed, if the power of the IOL is not ideal then one can correct the sphere from -3.00 to +3.00 D or astigmatism up to 3 D to refine the patient's uncorrected vision. In addition, the UV light can be used to induce a change to reduce spherical aberration and potentially enhance reading vision.

Corrections of refractive errors in pseudophakes

Enhancing a patient's vision following lens implant surgery can be done by an IOL exchange, laser vision correction, or a secondary IOL in the sulcus.⁵² Rayner Sulcoflex IOLs can be custom-made to correct almost any refractive error.⁵³ The lens has a 6.5 mm optic, a length of 14 mm, and is available in either monofocal or toric design. It has a concave posterior surface. Future trifocal implants will be inserted in the sulcus in pseudophakes. This will allow refinement of distance vision and improvement in both intermediate and near vision.

Corneal Inlays

Corneal inlays have faced many challenges. Early inlays were associated with corneal opacification, vascularization, keratolysis, and decentration.^{54,55} The inlay must be thin, have a small diameter, allow adequate nutritional and fluid permeability, and inserted relatively deep in the cornea. The long-term success of inlays depends on biocompatibility and providing excellent refractive outcomes and quality of vision. The most commonly used implant today is the KAMRA inlay, which is a small aperture inlay that enhances the depth of focus and is inserted deep in the cornea. Better outcomes are associated with insertion into a corneal pocket versus under a LASIK flap. The inlay is made of polyvinyl-

dene fluoride. The reported clinical results have been highly variable, and many surgeons have abandoned the procedure because of either early or late complications. The KAMRA inlay has a diameter of 3.8 mm, thickness of 5 μ m, and a 1.6-mm central opening.

The Raindrop inlay is 2 mm in diameter and 25 μ m thick. Unlike the KAMRA inlay, it induces central steeping to allow enhanced reading with pupillary constriction during accommodation.^{54,55} Although the early clinical results with the Raindrop were promising, a high percentage of patients developed a late reaction with corneal haze, necessitating explantation. Thus, the Raindrop inlay has been recently abandoned by ophthalmic surgeons.

Recent efforts are being made to develop corneal inlays from human corneal tissue.^{56,57} Early clinical trials look promising and we look forward to long-term data on outcomes, quality of vision, and safety.

Corneal Laser for Macular Degeneration

Corneal photovitrification (CPV) is a novel corneal laser procedure for improving vision in patients with age-related macular degeneration (AMD) and other conditions with central visual loss. This is a corneal refractive procedure that redirects light to preferred retinal locations in the macula with functioning photoreceptors (Figure 6). A 2017 case series demonstrated that a single treatment of CPV without visual training improved binocular and monocular near and distance vision effectively, safely, and comfortably from 1 to 12 months after CPV.⁵⁸ The treatment did not cause peripheral field restriction, diplopia, or other adverse events in patients with low vision from atrophic or neovascular AMD. Early Canadian clinical experience with the first approved CPV device in North America also demonstrated improved visual function, enhanced quality of life, and excellent safety in dry AMD patient with no epithelial defects or other complications.⁵⁹ Patient selection and testing for CPV are evolving, but this procedure offers the potential to help patients not only with AMD but also those with low vision from Best disease, Stargardt disease, macular holes and other retinal disorders with central loss of vision.

Summary

Recent refractive surgery has shown significant innovations in technology and techniques to allow patients to be independent of glasses or contact lenses with a high degree

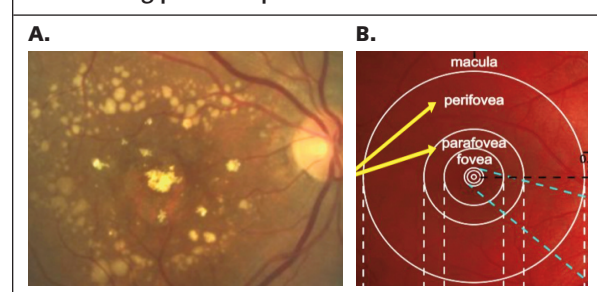
of accuracy and safety. Outcomes have improved because of advances in laser vision correction, phakic implants, corneal inlays, and RLE. New refractive innovations that were thought impossible are helping patients gain vision with AMD and other forms of central vision loss by redirecting light on the cornea to functioning photoreceptors. Refractive surgery is now mainstream in many continents around the world as an alternative to glasses and contact lenses. Efforts are being made to bring vision correction surgery to underdeveloped countries as a method of primary vision care. The field of refractive surgery is now considered a subspecialty in ophthalmology with the explosion of new information, technology, and surgeon skill required. The future looks very bright for patients who desire vision correction.

Dr. Raymond Stein is the Medical Director, Bochner Eye Institute, and an Associate Professor, Department of Ophthalmology and Vision Sciences, University of Toronto, Toronto, Ontario. Dr. Rebecca Stein is a Senior Ophthalmology Resident, University of Toronto, Toronto, Ontario.

References:

- Wynne J. Laser Refractive Surgery. Presented at the American Physical Society Annual Meeting. March 13-17, 2018: New Orleans, Louisiana.
- Yildirim Y, Olcucu O, Alagoz C, et al. Visual and refractive outcomes of photorefractive keratectomy and small incision lenticule extraction (SMILE) for myopia. *J Refract Surg*. 2016;32(9):604-610.
- Chua D, Htoon HM, Lim L, et al. Eighteen-year prospective audit of LASIK outcomes for myopia in 53 731 eyes. *Br J Ophthalmol*. 2018 Oct 23 [Epub ahead of print]
- Dupps WJ. LASIK outcomes: how are we doing and can we do better? *J Cataract Refract Surg*. 2016;42(8):1109-1110.
- Sandoval HP, Donnenfeld ED, Kohnen T, et al. Modern laser in situ keratomileusis outcomes. *J Cataract Refract Surg*. 2016;42(8):1224-1234.
- Bohac M, Koncarevic M, Pasalic A, et al. Incidence and clinical characteristics of post LASIK ectasia: a review of over 30,000 LASIK cases. *Semin Ophthalmol*. 2018;33(7-8):869-877.
- Smadja D, Santhiago MR, Mello GR, et al. Influence of the reference surface shape for discriminating between normal corneas, subclinical keratoconus, and keratoconus. *J Refract Surg*. 2013;29(4):274-281.
- Santhiago MR, Smadja D, Wilson SE, Randleman JB. Relative contribution of flap thickness and ablation depth to the percentage of tissue altered in ectasia after laser in situ keratomileusis. *J Cataract Refract Surg*. 2015; 41(11):2493-2500.
- Randleman JB, Russell B, Ward MA, et al. Risk factors and prognosis for corneal ectasia after LASIK. *Ophthalmology*. 2003;110(2):267-275.
- Randleman JB, Khandelwal SS, Hafezi F. Corneal cross-linking. *Surv Ophthalmol*. 2015;60(6):509-523.
- Sekundo W, Kunert KS, Blum M. Small incision corneal refractive surgery using the small incision lenticule extraction (SMILE) procedure for the correction of myopia and myopic astigmatism: results of a 6 month prospective study. *Br J Ophthalmol*. 2011;95(3):335-339.
- Recchioni A, Hartwig A, Dermott J, et al. Early clinical outcomes after small incision lenticule extraction surgery (SMILE). *Cont Lens Anterior Eye*. 2018; 41(1):132-135.
- Reinstein DZ, Carp GI, Archer TJ, Vida RS. Outcomes of re-treatment by LASIK after SMILE. *J Refract Surg*. 2018;34(9):578-588.
- Kanellopoulos AJ. Topography-guided LASIK versus small incision lenticule extraction: long-term refractive and quality of vision outcomes. *Ophthalmology*. 2018;125(10):1658-1659.
- Moshirfar M, Murri MS, Shah TJ, et al. Initial single-site surgical experience with SMILE: a comparison of results to FDA SMILE, and the earliest and latest generation of LASIK. *Ophthalmol Ther*. 2018;7(2):347-360.
- Shetty R, Matalia H, Nandini C, et al. Wavefront-guided LASIK has comparable ocular and corneal aberrometric outcomes but better visual acuity outcomes than SMILE in myopic eyes. *J Refract Surg*. 2018;34(8):527-532.
- Khalifa MA, Ghoneim A, Shaheen MS, et al. Comparative analysis of the clinical outcomes of SMILE and wavefront-guided LASIK in low and moderate myopia. *J Refract Surg*. 2017;33(5):298-304.
- Shen Z, Zhu Y, Song X, et al. Dry eye after SMILE versus FS-LASIK for myopia: a meta-analysis. *PLoS One*. 2016;11(12):e0168081.
- Zhang Y, Shen Q, Jia Y, et al. Clinical outcomes of SMILE and FS-LASIK used to treat myopia: a meta-analysis. *J Refract Surg*. 2016;32(4):256-265.

Figure 6. A. The goal of the Corneal laser for AMD is to relocate the image to the preferred retinal fixation point. **B.** Success of the treatment depends on some functioning photoreceptors outside of the fovea.



20. Kobashi H, Kamiya K, Shimizu K. Dry eye after small incision lenticule extraction and femtosecond laser-assisted LASIK: meta-analysis. *Cornea*. 2017;36(1):85-91.
21. Demirok A, Ozgurhan EB, Agca A, et al. Corneal sensation after corneal refractive surgery with small incision lenticule extraction. *Optom Vis Sci*. 2013;90(10):1040-1047.
22. Ambrósio RJ, Tervo T, Wilson SE. LASIK-associated dry eye and neurotrophic epitheliopathy: pathophysiology and strategies for prevention and treatment. *J Refract Surg*. 2008;24(4):396-407.
23. Savini G, Barboni P, Zanini M, Tseng SC. Ocular surface changes in laser in situ keratomileusis-induced neurotrophic epitheliopathy. *J Refract Surg*. 2004;20(6):803-809.
24. Denoyer A, Landman E, Trinh L, et al. Dry eye disease after refractive surgery: Comparative outcomes of small incision lenticule extraction versus LASIK. *Ophthalmology*. 2015;122(4):669-676.
25. Kanellopoulos AJ. Comparison of corneal biomechanics after myopic small-incision lenticule extraction compared to LASIK: an ex vivo study. *Clin Ophthalmol*. 2018;12:237-245.
26. Spuru B, Kling S, Hafezi F, Sekundo W. Biomechanical properties of human cornea tested by two-dimensional extensimetry ex vivo in fellow eyes: femtosecond laser-assisted LASIK versus SMILE. *J Refract Surg*. 2018;34(6):419-423.
27. Sinha Roy A, Dupps WJ Jr, Roberts CJ. Comparison of biomechanical effects of small-incision lenticule extraction and laser in situ keratomileusis: finite-element analysis. *J Cataract Refract Surg*. 2014;40(6):971-980.
28. Jonker SM, Berendschot TT, Ronden AE, et al. Long-term endothelial cell loss in patients with artisan myopia and artisan toric phakic intraocular lenses: 5- and 10-year results. *Ophthalmology*. 2018;125(4):486-494.
29. Kojima T, Kitazawa Y, Nakamura T, et al. Prospective randomized multicenter comparison of the clinical outcomes of V4c and V5 implantable collamer lenses: a contralateral eye study. *J Ophthalmol*. 2018;2018:7623829.
30. Igarashi A, Shimizu K, Kamiya K. Eight-year follow-up of posterior chamber phakic intraocular lens implantation for moderate to high myopia. *Am J Ophthalmol*. 2014;157(3):532-539.
31. Lee J, Kim Y, Park S, et al. Long term clinical results of posterior chamber phakic intraocular lens implantation to correct myopia. *Clin Exp Ophthalmol*. 2016;44(6):481-487.
32. Gimbel HV, LeClair BM, Jabo B, Marzouk H. Incidence of implantable Collamer lens-induced cataract. *Can J Ophthalmol*. 2018;53(5):518-522.
33. Alió JL, Grzybowski A, El Aswad A, Romaniuk D. Refractive lens exchange. *Surv Ophthalmol*. 2014;59(6):579-598.
34. Hengerer FH, Conrad-Hengerer I. Refractive lens exchange. *Klin Monbl Augenheilkd*. 2017;234(10):1299-1314.
35. Rosen E, Alió JL, Dick HB, et al. Efficacy and safety of multifocal intraocular lenses following cataract and refractive lens exchange: metaanalysis of peer-reviewed publications. *J Cataract Refract Surg*. 2016;42(2):310-328.
36. Venter JA, Pelouskova M, Collins BM, et al. Visual outcomes and patient satisfaction in 9366 eyes using a refractive segmented multifocal intraocular lens. *J Cataract Refract Surg*. 2013;39(10):1477-1484.
37. Bjerrum SS, Mikkelsen KL, La Cour M. Risk of pseudophakic retinal detachment in 202,226 patients using the fellow nonoperated eye as reference. *Ophthalmology*. 2013;120(12):2573-2579.
38. Schallhorn SC, Schallhorn JM, Pelouskova M, et al. 2017. Refractive lens exchange in younger and older presbyopes: comparison of complication rates, 3 months clinical and patient-reported outcomes. *Clin Ophthalmol*. 2017;11:1569-1581.
39. Kessel L, Andresen J, Tendal B, et al. Toric intraocular lenses in the correction of astigmatism during cataract surgery: a systematic review and meta-analysis. *Ophthalmology*. 2016;123(2):275-286.
40. Khan MI, Muhtaseb M. Prevalence of corneal astigmatism in patients having routine cataract surgery at a teaching hospital in the United Kingdom. *J Cataract Refract Surg*. 2011;37(10):1751-1755.
41. Rydström E, Westin O, Koskela T, Behndig A. Posterior corneal astigmatism in refractive lens exchange surgery. *Acta Ophthalmol*. 2016;94(3):295-300.
42. Savini G, Schiano-Lomoriello D, Balducci N, Barboni P. Visual performance of a new extended depth-of-focus intraocular lens compared to a distance-dominant diffractive multifocal intraocular lens. *J Refract Surg*. 2018;34(4):228-235.
43. Kohnen T, Hemkeppeler E, Herzog M, et al. Visual outcomes after implantation of a segmental refractive multifocal intraocular lens following cataract surgery. *Am J Ophthalmol*. 2018;191:156-165.
44. McNeely RN, Pazo E, Spence A, et al. Visual quality and performance comparison between 2 refractive rotationally asymmetric multifocal intraocular lenses. *J Cataract Refract Surg*. 2017;43(8):1020-1026.
45. Alió JL, del Barrio JL, Vega-Estrada A. Accommodative intraocular lenses: where are we and where we are going. *Eye Vis*. 2017;4(1):16.
46. Findl O, Hirschschall N. Accommodating intraocular lenses. In: Artal P (ed.). *Handbook of Visual Optics. Volume 2: Instrumentation and Vision Correction*. Boca Raton: CRC Press; 2017:211.
47. Dick HB, Piovella M, Vukich J, et al. Prospective multicenter trial of a small-aperture intraocular lens in cataract surgery. *J Cataract Refract Surg*. 2017;43(7):956-968.
48. Agarwal S, Thornell EM. Cataract surgery with a small-aperture intraocular lens after previous corneal refractive surgery: Visual outcomes and spectacle independence. *J Cataract Refract Surg*. 2018;44(9):1150-1154.
49. Trindade CC, Trindade BC, Trindade FC, et al. New pinhole sulcus implant for the correction of irregular corneal astigmatism. *J Cataract Refract Surg*. 2017;43(10):1297-1306.
50. Villegas EA, Alcon E, Rubio E, et al. Refractive accuracy with light-adjustable intraocular lenses. *J Cataract Refract Surg*. 2014;40(7):1075-1084.
51. Ford J, Werner L, Mamalis N. Adjustable intraocular lens power technology. *J Cataract Refract Surg*. 2014;40(7):1205-1223.
52. Sáles CS, Manche EE. Managing residual refractive error after cataract surgery. *J Cataract Refract Surg*. 2015;41(6):1289-1299.
53. Prager F, Amon M, Wiesinger J, et al. Capsular bag-fixated and ciliary sulcus-fixated intraocular lens centration after supplementary intraocular lens implantation in the same eye. *J Cataract Refract Surg*. 2017;43(5):643-647.
54. Moarefi MA, Bafna S, Wiley W. A review of presbyopia treatment with corneal inlays. *Ophthalmol Ther*. 2017;6(1):55-65.
55. Mulet ME, Alió JL. Corneal inlays: complications. In: Alió J, Azar DT, eds. *Management of Complications in Refractive Surgery*. Cham: Springer; 2018: 389-394.
56. Liu YC, Teo EP, Ang HP, et al. Biological corneal inlay for presbyopia derived from small incision lenticule extraction (SMILE). *Sci Rep*. 2018;8(1):1831.
57. Jacob S, Kumar DA, Agarwal A, et al. Preliminary evidence of successful near vision enhancement with a new technique: Presbyopic Allogenic Refractive Lenticule (PEARL) corneal inlay using a SMILE lenticule. *J Refract Surg*. 2017;33(4):224-229.
58. Serdarevic O, Tasindi E, Dekaris I, Berry M. Vision improvement in dry and wet age related macular degeneration (AMD) patients after treatment with new corneal CPV procedure for light redirections onto the retina. *Acta Ophthalmologica*. 2017;95:S259.
59. Stein R, Markowitz S, Gilani F. Corneal Laser for Macular Degeneration. *Pre-cision Ophthalmology*, Columbia University, Manhattan, NY, Nov 30, 2018.

The authors declare that they have no relevant financial interests to disclose.

Change of address notices and requests for subscriptions for *Ophthalmology Rounds* are to be sent by mail to P.O. Box 310, Station H, Montreal, Quebec H3G 2K8 or by fax to (514) 932-5114 or by e-mail to info@snellmedical.com. Please reference *Ophthalmology Rounds* in your correspondence. Undeliverable copies are to be sent to the address above. Publications Post #40032303

Ophthalmology Rounds is made possible through educational support from
Novartis Pharmaceuticals Canada Inc.